

Clinical research with the rtx1™ Adaptive Optics retinal camera

Summary of published results in **diabetic retinopathy**

The detection of early damage to organs is of key importance in the management of diabetes.

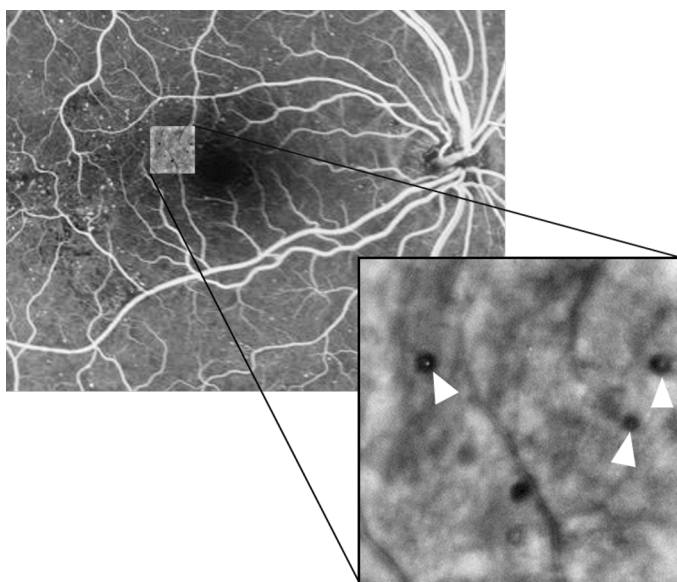
The rtx1™, thanks to adaptive optics (AO) technology, has enabled visualizing multiple early alterations caused by diabetes to the retina, often before any damage is visible using other retinal imaging techniques.

Clinical studies using the rtx1 have resulted in several new findings:

- rtx1 images revealed microscopic hemorrhages^{1,2,3}, non-flowing blood cells¹, edematous cyst walls¹, and modified arteriolar structure⁴⁻⁶.
- Microaneurisms could also be visualized without injecting any contrast agent³.
- rtx1 images allowed using new biomarkers* for assessing retinal changes in diabetic patients, including modifications in capillary diameter⁵ and in the density of visible photoreceptors^{2,7,8}.
- Such microscopic signs of pathology were observed not only in diabetic retinopathy (DR)^{1-3,5,7}, but also at earlier stages, including diabetes without DR^{2,4,7,8} and pre-diabetic conditions⁶.

” AO imaging may potentially assist in detecting diabetic retinopathy at an earlier stage, may help elucidating the pathophysiology of the diseases and may be used for evaluating the effects of clinical interventions on diabetic retinopathy

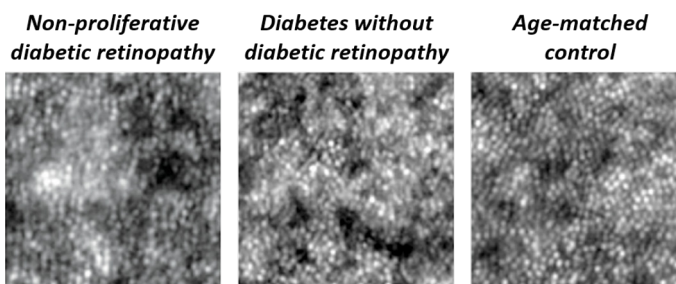
Bek et al. *Acta Ophthalmologica*, 2014



Top: Fluorescein angiography image in a case of diabetic retinopathy. Overlay: Microaneurisms (arrows) imaged without contrast agent with the rtx1. Credit: Quinze-Vingts National Eye Hospital, Paris

” [...] an exquisitely fine documentation of microscopic features such as microaneurysms, microhemorrhages, and hard exudates can also be obtained with adaptive optics ophthalmoscopy

Paques et al. *Prog in Retina and Eye Res*, 2018



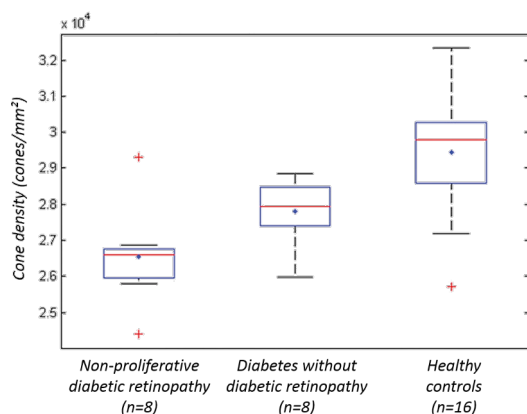
Changes in photoreceptor visibility revealed by the rtx1 in diabetic patients compared to age-matched control. Credit: Lombardo et al. 2016

” Detection of photoreceptor loss at early stages of diabetic retinopathy may contribute to changing the current standard regimen of treatment via earlier intervention to stop further damage

Soliman et al. *PLOS ONE*, 2016

Clinical research with the rtx1™ AO camera

Summary of published results in **diabetic retinopathy**



Box plot showing the distribution of values for cone density measured on rtx1 images, at 1.5 degrees eccentric from the fovea, in diabetic patients and age-matched controls. Credit: Lombardo et al. 2016

“ Our findings indicate that parafoveal cone density decreased by a mean of 1672 cones/mm² per step of diabetic retinopathy progression
Soliman et al. *PLOS ONE*, 2016

“ In all patients, AO images showed dark elements that were smaller than what could be resolved by fundus imaging and OCT. The smallest of these lesions were circular with a size corresponding to both leucocytes (diameter approximately 20 microns) and erythrocytes (diameter approximately 7 microns)

Bek et al. *Acta Ophthalmologica*, 2014

“ The average capillary lumen in eyes with non-proliferative diabetic retinopathy was 15% narrower than in healthy eyes of age-matched subjects

Lombardo et al. *Retina*, 2014

“ The retinal image analysis with rtx1 offers a novel noninvasive measurement of early changes in the vasculature that are not detectable on routine clinical examination. This measurement may allow the identification of individuals at risk of diabetes

Zaleska-Zmijewska et al. *Journal of Diabetes Research*, 2017

References

1. Bek, T. Fine Structure in Diabetic Retinopathy Lesions as Observed by Adaptive Optics Imaging. a Qualitative Study. *Acta Ophthalmologica* 92, 753–758 (2014).
2. Lombardo, M. et al. Adaptive Optics Imaging of Parafoveal Cones in Type 1 Diabetes. *Retina* 34, 546–557 (2014).
3. Paques, M. et al. Adaptive Optics Ophthalmoscopy: Application to Age-Related Macular Degeneration and Vascular Diseases. *Progress in Retinal and Eye Research* 66, 1–16 (2018).
4. Rosenbaum, D. et al. Effects of Age, Blood Pressure and Antihypertensive Treatments on Retinal Arterioles Remodeling Assessed by Adaptive Optics. *Journal of Hypertension* 34, 1115–1122 (2016).
5. Lombardo, M. et al. Analysis of Retinal Capillaries in Patients with Type 1 Diabetes and Nonproliferative Diabetic Retinopathy Using Adaptive Optics Imaging. *Retina* 33, 1630–1639 (2013).
6. Zaleska-Zmijewska, A. et al. Retinal Photoreceptors and Microvascular Changes in Prediabetes Measured with Adaptive Optics (rtx1TM): A Case-Control Study. *Journal of Diabetes Research* 2017, 1–9 (2017).
7. Soliman, M. K. et al. High-Resolution Imaging of Parafoveal Cones in Different Stages of Diabetic Retinopathy Using Adaptive Optics Fundus Camera. *PLOS ONE* 11, e0152788 (2016).
8. Lombardo, M. et al. Investigation of Adaptive Optics Imaging Biomarkers for Detecting Pathological Changes of the Cone Mosaic in Patients with Type 1 Diabetes Mellitus. *PLOS ONE* 11, e0151380 (2016).



www.imagine-eyes.com

18 rue Charles de Gaulle
91400 Orsay, FRANCE
+33 (0) 1 64 86 15 66
contact@imagine-eyes.com

(*) Biomarkers based on adaptive optics retinal images have not been approved for clinical use. The rtx1 is an approved medical device in the European Union (device class 2a) and in Japan. In the USA, the rtx1 has not received FDA clearance. It is an investigational device and requires Institutional Review Board (IRB) oversight for use in any research application. Further information is provided in the user's documentation.